

## Epidemiology and Classification of Diabetic Retinopathy

Muhammad Faisal<sup>1</sup>, Djoko Wahono<sup>2</sup>

<sup>1</sup> Informatics Engineering, Faculty of Science and Technology, UIN Maulana Malik Ibrahim Malang

<sup>2</sup> Faculty of Medical, Brawijaya University, Malang, East Java

**Indonesia**

Email : muhfais@yahoo.com

**Abstract** Diabetes Mellitus is a degenerative disease that occurs in almost all organs. The disease is caused by blood sugar levels higher than normal (60 mg / dl - 145 mg / dl), glucose can not manage cells due to a deficiency or insulin resistance.

Changes in the structure of the pattern from agrarian to industrial society and changing fertility patterns of socio-economic lifestyles and communities suspected as being behind the prevalence of Diseases, thereby increasing the incidence of the disease varies in epidemiological transition. Diabetes Mellitus is a disease whose prevalence is increasing from year to year. Diabetes mellitus can affect every organ system and cause a variety of complications. Chronic Complications of Diabetes Mellitus that the eye disease called diabetic retinopathy.

Diabetic retinopathy is an eye disease that is very scary for young children to adults. Indonesia as a developing country, is one of the countries with the degenerative disease prevalence increased most rapidly. Diabetic retinopathy is a disease that impacts more serious because it can cause blindness.

This study gives an overview epidemiology of the retinopathy diabetic disease and provides description of the classification of diabetic retinopathy.

Keywords: *Diabetic retinopathy, degenerative, chronic complications*

### 1. Introduction

Diabetes mellitus, more popularly known as diabetes is one of the non-communicable diseases caused by disorders of insulin production by the pancreas gland or malfunction of the hormone insulin. The hormone insulin is used to adjust the balance glukosa in the blood. As a result of the disruption of insulin production there is an increase in blood glucose above the normal threshold [1].

Many reports from countries around the world that shows the increase in the number of people with diabetes. The number of patients with diabetes mellitus has reached 285 million people worldwide and in Indonesia reached 6,963,500 people [2]. Keep in mind this disease not only attacks the upper middle class, but also attack the economically weak. So, this disease has become a frightening threat to countries around the world.

Results Health Research (Riskesdas) in 2007, found that the proportion of the cause of death due to diabetes in the age group 45-54 years in urban areas was ranked second is 14.7%. And rural areas, DM ranks sixth is 5.8%. Population studies DM patients in various countries, Indonesia occupies the fourth position with the number of about 8.4 million in 2004. The population study conducted the World Health Organization (WHO) in the said Indonesia was in fourth position behind India (3, 1 million people), China (20.8 million people), and the US (17.7 million people). It is estimated that the prevalence of diabetes will continue to increase in tandem with changes in lifestyle and food consumption patterns. In 2030 in India are predicted 79.4 million diabetic patients, China 42.3 million, 30.3 million US, and Indonesia 21.3 million people (WHO, 2004).

### 2. Effect of Diabetes Mellitus

The effects of diabetes mellitus include long-term damage, dysfunction, and failure of various organs, especially the eyes, kidneys, heart, and blood vessels. Diabetes can be present with typical symptoms such as thirst, polyuria, blurred vision, weight loss, and polyphagia, and in the most severe form, with ketoacidosis or nonketotic hyperosmolarity, which, in the absence of effective treatment, leading to stupor, coma, and death. Often symptoms are not severe or may not even exist. Hyperglycemia enough to cause functional changes may quite often present pathological until long time before being diagnosed. As a result, diabetes is often found any abnormal results of routine blood or urine glucose tests or due to complications. In some cases of diabetes may not be seen only occasionally, such as, for example, with glucose intolerance in pregnancy or gestational diabetes, which can berpengaruh after parturition. In some individuals the possibility of developing diabetes can be recognized even before any obvious abnormalities of glucose tolerance. During the evolution of type 1 diabetes, for example, immunological disorders such as islet cells or other antibody is present, and this may precede clinically apparent disease by months or even years [3].

### 3. Diabetic Retinopathy Epidemiology

Based on The DiabCare Asia 2008 Study, 42% of people with diabetes in Indonesia had complications of retinopathy [4]. The number is different in various regions in Indonesia. In RS M. Djamil Padang, approximately 50.7% of DM patients experienced RD, both non-proliferative or proliferativ [5].

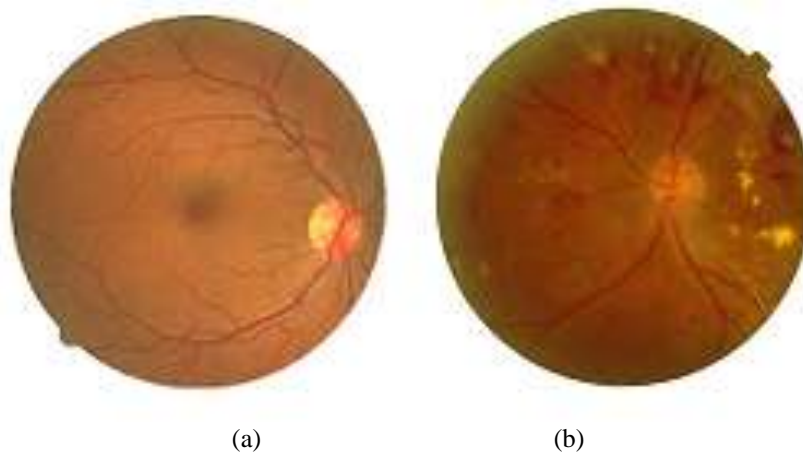
The risk of developing retinopathy increases after puberty. In the Wisconsin Epidemiologic Study of Diabetic Retinopathy (WESDR), 3.6% of younger-onset patients (type 1 diabetes) and 1.6% of older-onset patients (type 2 diabetes) were legally blind. In the younger-onset group, 86% of blindness was attributable to diabetic retinopathy. In the older-onset group, in which other eye diseases were common, one-third of the cases of legal blindness were due to diabetic retinopathy [6].

### 4. Classification of Diabetic Retinopathy

The main complication of diabetes eye is called diabetic retinopathy and occurs in patients who have had diabetes for at least five years. Small blood vessels are damaged causing leakage of protein and blood in the retina. The result could also lead to the formation of small aneurysms (microaneurysms), and new blood vessels but fragile (neovascularization). Spontaneous bleeding from the new blood vessels and can lead to brittle scarring the retina and retinal detachment, so damage eyesight.

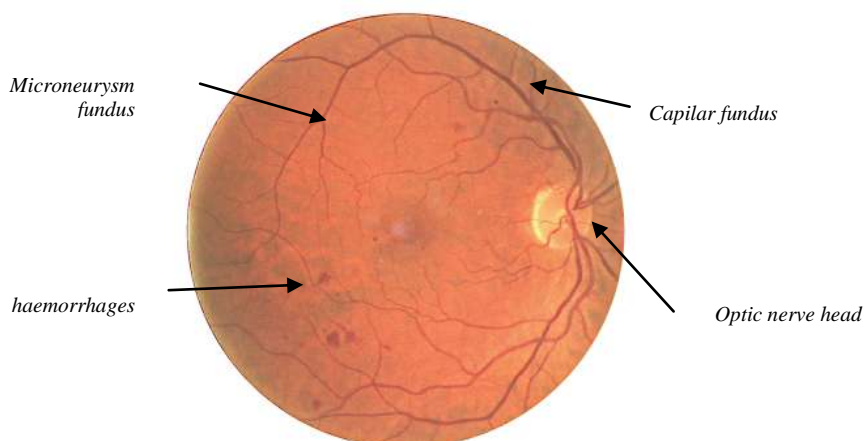
So far we know only the blood vessel blockage occurs in the brain (stroke). It turns out that this condition can also occur in the eye. If not treated immediately, the stroke of the eye will impair vision and cause blindness, blockage of blood vessels in retinal eye make bleed.

Diabetic retinopathy is classified into 3 types: namely Background diabetic retinopathy (BDR), proliferate diabetic retinopathy (PDR) and Severe Diabetic Retinopathy (SDR). Stage Background Diabetic Retinopathy weakened arteries in the retina and leak small, such as point haemorrhages. Leaking vessel encourage or eudema retinal swelling and reduce visual acuity. Phase proliferate diabetic retinopathy, circulation problems or ischemic oxygen deficiency. vessels dilate to maintain the circulation of oxygen in the retina. This event is called neovascularisation. Severe stages of diabetic retinopathy abnormal vessel growth continued sehingga cause serious problems such as retinal detachment, glaucoma and vision gradually becomes opaque [7].



**Figure 1.** (a) Normal Retinal fundus image (b) *Diabetic Retinopathy*

Figure 1(a) shows the visual form of a normal eye with large eye blood vessels (capillaries) and small blood vessels (microaneurysm) perfect.



**Figure 2.** Structure of the infected eyes Abnormal result Diabetic retinopathy

Figure 2 shows the damage to the small blood vessels are indicated as eye disease diabetic retinopathy in group haemorrhage.

One of the early signs of diabetic retinopathy is the emergence of microaneurysm. Microaneurysm arise due to weakening of the vessel wall smallest. Injuries that occur on the vessel causes the formation of exudates is a point that looks yellowish around the retina. Symptoms that can be found can be: difficulty reading, blurred vision, decreased eyesight suddenly in one eye, seeing halos, see dark spots and light flashes [7]. This phenomenon occurs because there is seepage of blood retinal eye lens.

Laser therapy is used to treat and control diabetes, the manual method is required expensive and require trained ophthalmologist [8].

## 5. Conclusion

1. Indonesia is the fourth country after India, China and the United States as the disease Diabetes Mellitus with 8.4 percent in 2000 and is expected to increase the percentage in 2030 sebesar 21.3%.
2. The main cause of Diabetes Mellitus occurs affected by uncontrolled blood glucose due to the factor of obesity, hypertension, knowledge, lifestyle, and so on.  
Blindness due to diabetic retinopathy
3. can be minimized by knowing the symptoms of diabetic retinopathy at an early stage.

## 6. Suggestions

1. Treatment of Diabetes Mellitus so presumably can really be taken seriously, so as to reduce the number of deaths from the disease of Diabetes Mellitus.
2. Need for early examination of a more responsible about the importance of blood sugar control in individuals who have risk factors.

## References

- [1] ADA, 2009. Total Prevelensi of Diabetes, American Diabetes Association, *Http Wwwdiabetesorgabout-Diabetesjsp*.
- [2] IDF, 2009. Regional estimates for diabetes(20-79 years), 2010 and 2030,
- [3] M. Rewers, J. M. Norris, G. S. Eisenbarth, H. A. Erlich, B. Beaty, G. Klingensmith, M. Hoffman, L. Yu, T. L. Bugawan, A. Blair, and others, 1996. Beta-cell autoantibodies in infants and toddlers without IDDM relatives: Diabetes Autoimmunity Study in the Young (DAISY), *J. Autoimmun.*, vol. 9, no. 3, pp. 405–410
- [4] Soewondo P, Soegondo S, Suastika K, Pranoto A, Soeatmadji and DW, Tjokroprawiro A. 2010. “The DiabCare Asia 2008 study - Outcomes on control and complications of type 2 diabetic patients in Indonesia.” *Med J Indon*, vol. 19, no. 4, pp. 235–43
- [5] Rahman K. 2002. Epidemiologi retinopati diabetika di Bagian Ilmu Penyakit Mata Fakultas Kedokteran Universitas Andalas/Perjan RS Dr. M. Djamil Padang, *Maj. Kedokt. Andalas*, vol. 26, pp. 49–58
- [6] D. S. Fong, L. Aiello, T. W. Gardner, G. L. King, G. Blankenship, J. D. Cavallerano, F. L. Ferris, and R. Klein, 2004. Retinopathy in diabetes, *Diabetes Care*, vol. 27, no. suppl 1, pp. s84–s87

- [7] Aibinu, A.M, Gubbal, N.S, Khan, 2006. "Automatic Diagnosis of Diabetic Retinopathy using Fundus Citras," *Blekinge Inst. Technol.*
- [8] Akara Sopharak, 2007. Automatic Exudates Detection From Diabetic Retinopathy Retinal Citra Using Fuzzy C-Means And Morphological Methods, *Adv. Comput. Sci. Technol. Thail.*